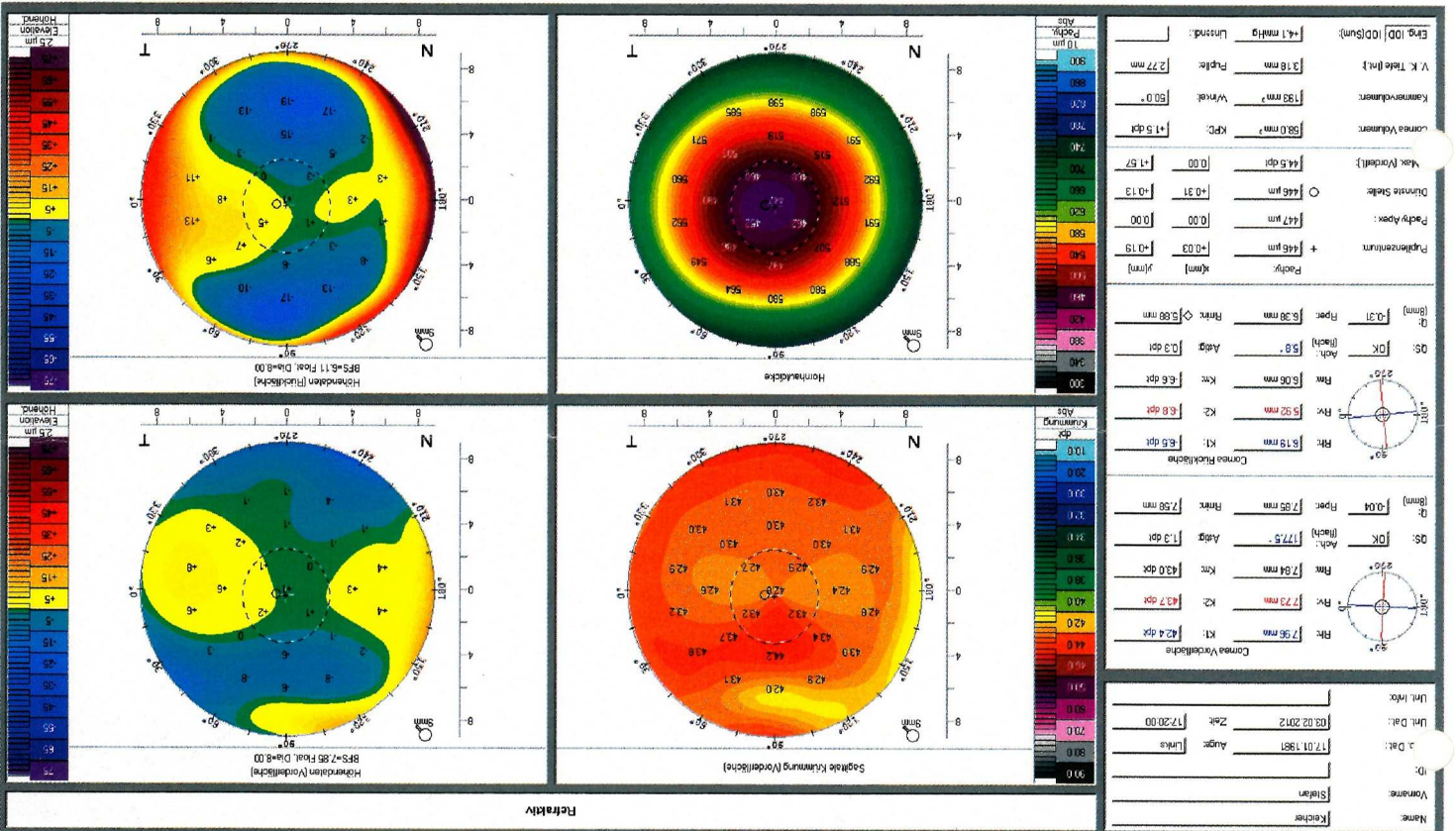
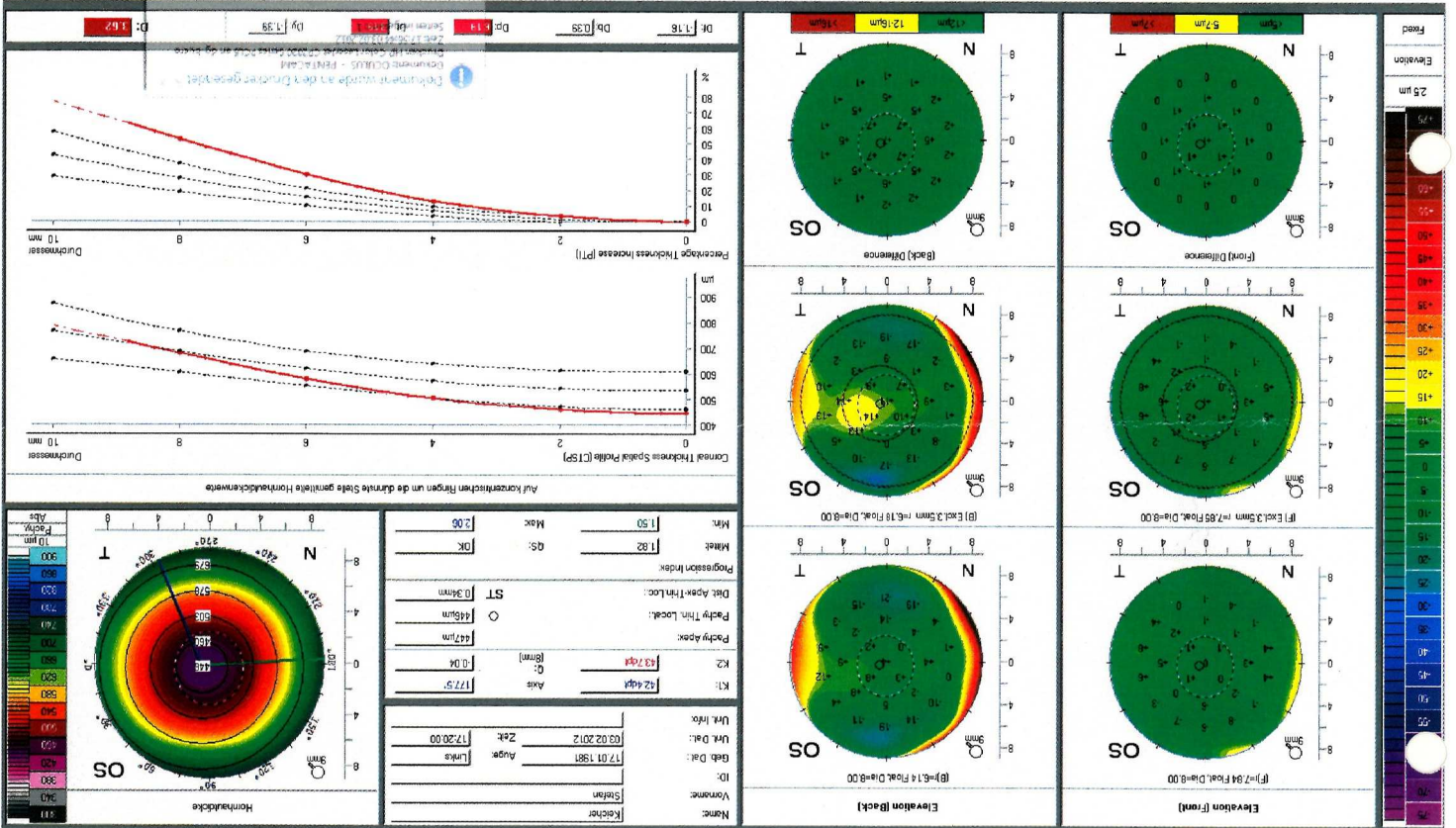


OCULUS - PENTACAM



OCULUS - PENTACAM



Belin / Ambrosio Enhanced Ectasia

OCULUS - PENTACAM

PD Dr. Dr. Kirsten Reinhard
 Fachärztin für Augenheilkunde
 Ambulante Operationen
 Kaiserstr. 49 - 72764 Reutlingen
 Tel. 07121 / 33 82 25 - Fax 34 69 16

Name: Keicher
 Vorname: Stefan
 Datum: 17.01.1981
 Auge: Rechte
 Uml. Dat.: 02.02.2012
 Zahl: 17-18-23

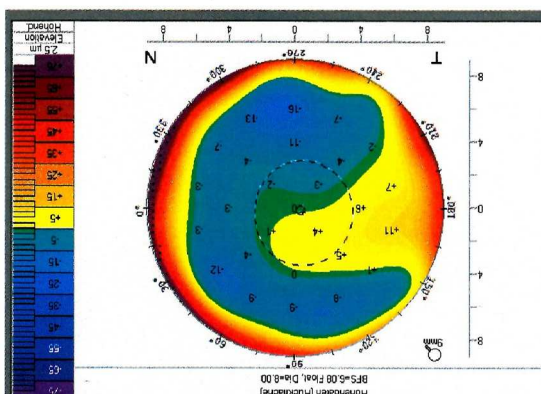
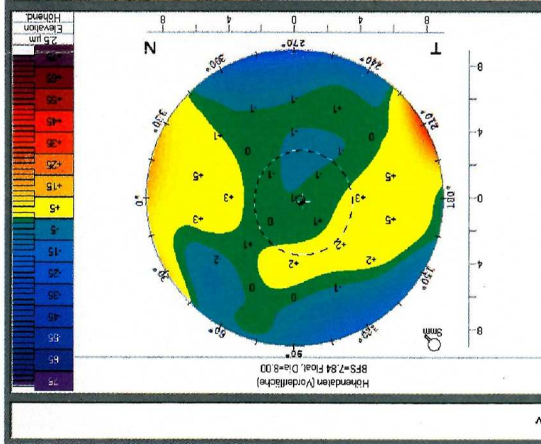
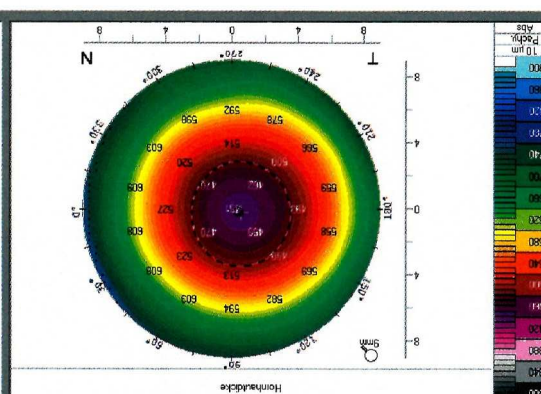
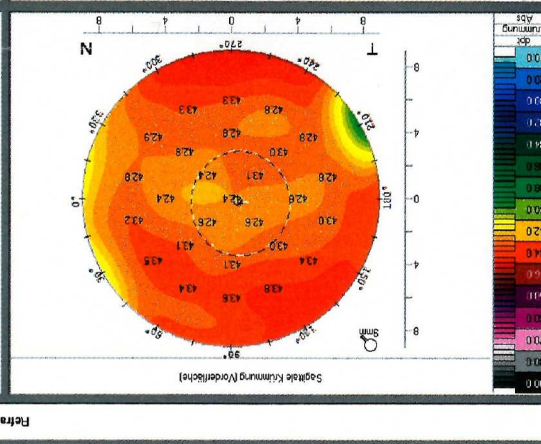
Cornea Vorderlinde
 RH: 7,95 mm
 K1: 42,4 dpt
 K2: 42,8 dpt
 Rmc: 7,92 mm
 Kmc: 42,6 dpt
 Achs. (Rad.): 162,1°
 Asph: 0,4 dpt
 Rmr: 7,15 mm
 Fipcr: 0,11 (mm)

Cornea Rücklinde
 RH: 8,11 mm
 K1: 43,5 dpt
 K2: 43,7 dpt
 Rmc: 8,05 mm
 Kmc: 43,6 dpt
 Achs. (Rad.): 156,5°
 Asph: 0,1 dpt
 Rmr: 5,86 mm
 Fipcr: 0,36 (mm)

Papillenlinde
 Ppccy: 4,50 µm
 Ppccy: 4,27 µm
 Ppccy: 4,14 µm
 Ppccy: 4,00 µm
 Ppccy: 0,00 µm
 Ppccy: 0,00 µm
 Ppccy: 0,19 µm
 Ppccy: 0,37 µm

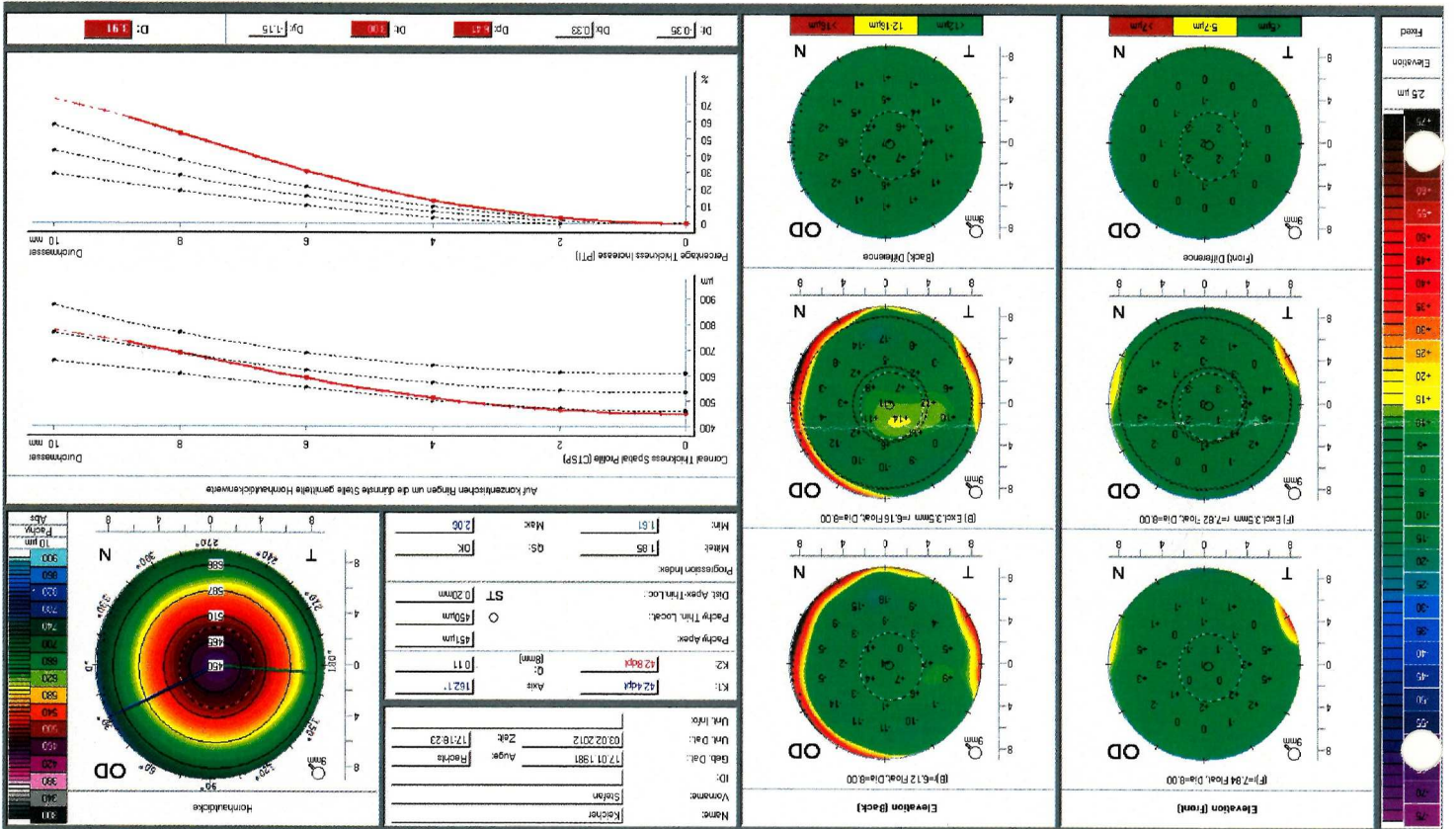
Cornea Volumen
 KPD: 11,8 dpt
 Vkr: 29,2°
 Kammerwinkel: 1,98 mm²
 Vkr: 3,07 mm
 Fipcr: 3,13 mm
 Umrund.: 4,0 mm²

Erhg. IOD (IOD(Sum))
 V. K. Tiele (ml): 3,13 mm
 Fipcr: 3,07 mm
 Umrund.: 4,0 mm²



Refraktiv

OCULUS - PENTACAM



Belin / Ambrósio Enhanced Ectasia